ISSN 2466-0167
Asian J Pain 2016;2(1):22-28

CLINICAL ARTICLE

AJP

A Rapid Pain Management and Possible Mechanism of Severe Acute Low Back Pain after Traumatic Event : A Comparative Analysis of Spinal Injection Therapy with Segmental 3-Column Theory

Hyeun Sung Kim[1], Kun Soo Jang[2]✉

[1]Department of Neurosurgery, Nanoori Hospital, Suwon, Korea
[2]Department of Neurosurgery, 365 Yeollin Hospital, Taean, Korea

Objective: In case of severe acute low back pain (LBP) after traumatic event, early effective management is unknown because mechanism of acute LBP has yet to be established. The purposes of this study were to evaluate the outcome of spinal injection therapy according to segmental 3-column theory and to discuss the possible mechanism of acute LBP. **Methods:** This prospective study included 235 patients. All the patients had experienced a critical traumatic event such as lifting or snapping and had visual analogue scale (VAS) of 7 or greater. On the basis of the segmental 3-column concept, the patients were divided into 4 groups : group A, no segmental injection group; group B, 1-column injection group; group C, 2-column injection group; and group D, 3-column therapy group. Clinical outcomes were assessed by using the VAS. Total follow-up period was two weeks. Magnetic resonance imaging (MRI) scans were also evaluated before the treatment. **Results:** All the treatments of each group were shown to be statistically effective for control of acute LBP. But, compared to that in other groups, the decrease in the VAS score of group D (3-column therapy group) was statistically significant. And, derangement patterns of the intervertebral disc were observed on MRI in all groups. **Conclusion:** Severe acute LBP after the traumatic event is likely to occur from the segmental 3-column distress. Therefore, it would be better for patient to have the 3-column therapy. Additionally, internal disc derangement could be the measure to allow us to know the status of 3-column distress.

Key Words: Acute pain; Low back pain; Spinal injections; Spinal column; Intervertebral disc.

✉**Corresponding author:** Kun Soo Jang, Department of Neurosurgery, 365 Yeollin Hospital, 220 Dongbaek-ro, Taean-eup, Taean 32144, Korea.
Tel: 82-41-671-1365, Fax: 82-41-675-9708, E-mail: deme2000@naver.com

INTRODUCTION

Many people suffer from severe acute LBP after lifting or snapping at several points in their lifetime. Conservative treatments recommend to the patients. But these treatments typically don't help with severe acute LBP. It requires several weeks for the patients to get the satisfactory recovery[8]. For case in which the pain is severe, physicians commonly perform the interventional procedure like as spinal injection therapy including medial branch block (MBB) and epidural block for rapid pain relief[16]. Although widely used, the beneficial effect of spinal injection therapy on the clinical outcome has not been succeeded[27]. We believe that injection therapy should be administered depending on the mechanism of acute LBP. Lumbar flexion posture followed by lifting or snapping could result in the strongest loading to the vertebral segment. The 3-column, which is consisted of vertebral segment, is all influenced by this sudden loading simultaneously (Fig. 1). In this situation, we consider that increased flexion loading causes a change of the intradiscal integrity in the anterior column and this change would be able to be seen on MRI. Inflammation and dural irritation occurs at the middle column around sinuvertebral nerve. Finally, the posterior column shows ligament laxity and back muscle contraction we call the deep somatic derangement[17,33,38,42]. We consider that this 3-column distress is the most important underlying mechanism of severe acute LBP[31]. And we regard

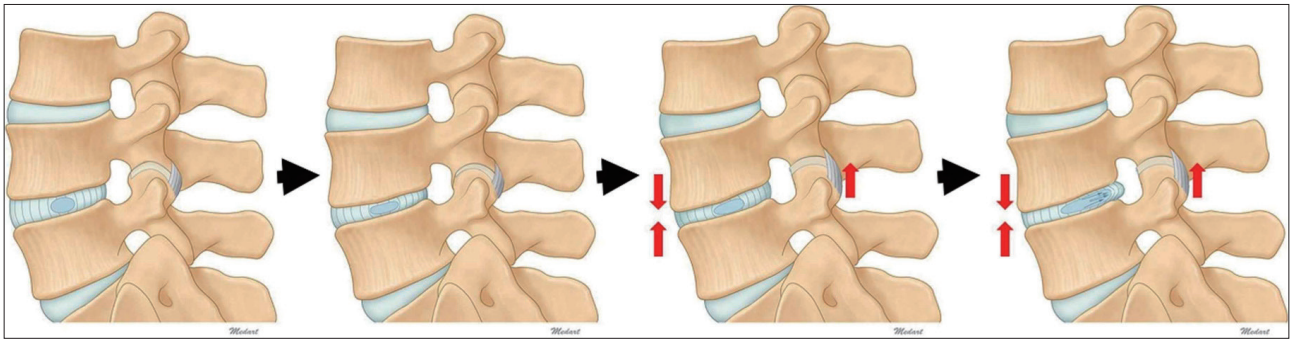

Fig. 1. Sequential diagrams showing compression of an anterior column and stretching of a posterior column simultaneously after flexion loading.

Table 1. Four groups of segmental injection therapy

	Column	Therapy	Initial mean VAS
Group A (n=45)	No injection group	Medication, physiotherapy, and bed rest	8.06
Group B (n=49)	1-column injection group	Epidural injection or medial branch injection	7.87
Group C (n=46)	2-column injection group	Epidural injection+medial branch injection	7.78
Group D (n=95)	3-column therapy group	Epidural injection+medial branch injection+postural reduction	7.76

this status of 3-column distress as micro-subluxation like chiropractic vertebral subluxation in the end[10,18]. Micro-subluxation is functional subluxation caused by the loss of segmental integrity unlike that observed in anatomical subluxation such as spondylolisthesis seen radiographically. We categorized injection therapy into 3 types according to the target column : 1, 2, and 3-column. We compared the outcome of the 3-column therapy group with that of another therapy group.

MATERIALS AND MATHODS

The patient population in this prospective study comprised 235 patients who had visited the institution between January 2011 and January 2012. At the time of study inclusion, all patients had severe acute LBP due to a segmental loading event such as lifting or snapping. The initial VAS of all patients was ≥7. Pain onset had occurred within 7 days prior to study inclusion. Patients who required surgical treatment were excluded owing to severe radiculopathy symptoms or spinal instability. Moreover, patients older than 50 years of age were excluded because of the expected age-related disc degeneration.

The patients were divided into 4 groups (Table 1). To assess the clinical result more definitely, we classify the VAS as following 4 groups : no (0), mild (1−3), moderate (4−6), and severe (7−10).

Epidural injection

The epidural injection was administered mainly using an interlaminar or transforaminal approach according to the vertebral level or the degree of spondylosis. We injected 6 cc of 0.5% lidocaine mixed with half an ample of methylprednisolone for clearing the chemical and neural irritation of middle column.

Medial branch injection

We used 15% dextrose solution for decreasing the deep somatic derangement of the posterior column. 3 cc of 50% dextrose solution was mixed with 2 cc of 1% lidocaine and 5 cc of normal saline. This solution was prepared on the basis of the regenerative injection therapy (RIT) concept. If L4−5 segment was affected, we injected the solution around the articular capsular ligament and medial branch at L3, 4, and 5. The amount of injected solution was 2 cc per each site.

Fig. 2. Postural reduction was performed using the pillow under the micro-subluxation point toward the natural lumbar curvature.

Postural reduction

Postural reduction was performed using a pillow under the lumbar curvature for achieving the sufficient restoration of micro-subluxation and decreasing of the internal disc pressure in the anterior column. The most effective time was before sleep and the maximal duration of reduction was 30 min. We recommended the patients to repeat several times a day if possible. The appropriate height of the pillow was about 8−10 cm. Patients were warned that the pain would aggravate for 3 to 7 days after postural reduction until reduction of micro-subluxation. We recommended daily reduction for more than 1 to 3 months to

Table 2. Clinical outcomes using the visual analogue scale (VAS)

		Group				*p*-value	Duncan
		A	B	C	D		
Follow-up period (week)	0	8.06	7.87	7.78	7.76	0.056	A>BCD
	1	4.87	4.78	4.17	3.71	<0.001	D<C<AB
	2	3.60	3.61	2.65	1.14	<0.001	D<C<AB
p-value		<0.001	<0.001	<0.001	<0.001		

the patients for achieving sufficient recovery from micro-subluxation (Fig. 2).

Radiographic assessment

All the patients underwent MRI and full lumbar X-ray series, including a functional view (flexion/extension), at the first visit. Their abnormal patterns of the nucleus of pulposus were evaluated with MRI. Patients with spinal instability were excluded.

Statistical analysis

We assessed the results using the VAS every week after treatment. Analysis of variance (ANOVA) was used for evaluating of the effectiveness of treatment in each group. The significance of difference between groups was evaluated by repeated measures analysis of variance (rANOVA). *p*-value of less than 0.05 was considered to be statistically significant. Post-hoc analysis was also performed using Duncan. IBM SPSS statistics 19 for Windows was the software used for the statistical analysis.

RESULTS

At initial visit, the VAS score of each group was similar. Rather the VAS score was higher in group D. At one week after treatment, the VAS score was statistically decreased in all groups ($p<0.001$). Group D showed the lowest VAS score when compared with the other groups ($p<0.001$). At two week after treatment, the VAS score was statistically decreased in all groups compared to last week. Group D also showed the lowest VAS score (Table 2). And there was significant difference of the VAS between Group D and the other Groups ($p<0.001$) (Fig. 3).

Changes in VAS for each group at the initial visit, one week after treatment, and two weeks after treatment are as follows (Fig. 4). Group D had the highest percentage (%) of no pain (VAS=0) and mild pain (VAS=1 to 3) scores after treatment.

MRI of all patients showed abnormal patterns of the nucleus of pulposus including crack and effluence.

DISCUSSION

For patients who present with severe acute LBP (VAS score ≥7) at a hospital, physicians commonly recommend spinal injection therapy for rapid pain relief. Medial branch block (MBB) and epidural block are selected universally for this purpose. The spinal segment is divided into three parts : anterior, middle, and posterior column[9]. The MBB is mainly targeted at the

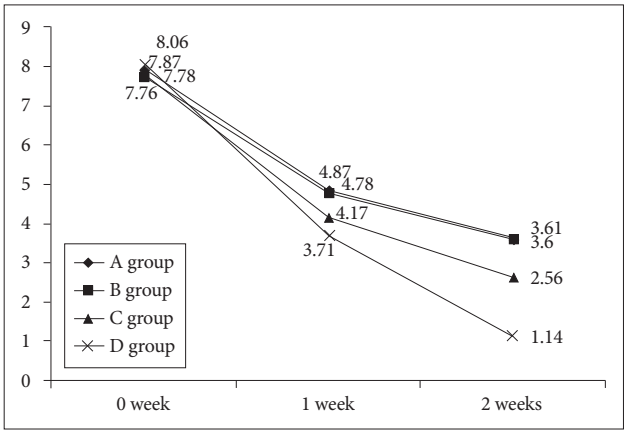

Fig. 3. In Group D, the visual analogue scale decline was statistically significant compared with other groups at 1 and 2 weeks later after treatment.

posterior column such as facet joints, stabilizing muscles, and ligaments[28]. The epidural block is injected into the middle column for sinuvertebral nerve block and washing out inflammatory cytokines[7,32,33].

We performed MBB by mixed with high osmotic glucose solution. The purpose of this solution was not only healing of facet capsular ligament but also to take a chemo-modulation and neuro-modulation of regenerative injection therapy (RIT) to medial branch[15,24]. RIT, also known as prolotherapy in the past, has a variable mechanism of action[25,26]. High osmolar glucose solution acts as a chemical irritant that initiates inflammation and causes collagen formation that is explained by chemomodulation of collagen in RIT. Prolotherapy characterizes this collagenous proliferation effect. RIT is a further theory including prolotherapy. RIT also has an effect of neuromodulation for peripheral nociceptors and antidromic, orthodromic, sympathetic and axon reflex transmissions[24]. So medial branch injection using high osmotic solution causes neuromodulation of unmyelinated branches from the dorsal primary ramus.

Although above two injection therapies were effective for treatment of acute LBP according to our study, these two injection therapies do not resolve the problems of the anterior column effectively. The problem of the anterior column is internal disc derangement. Internal disc disruption is well known as one of the causes of chronic LBP[6,33,38]. However, we also found abnormal patterns of intervertebral disc images on MRI scans of acute LBP patients with a history of lifting or snapping before they experience back pain in our study. The integrity of the nucleus pulposus was cracked. The water content of the affected

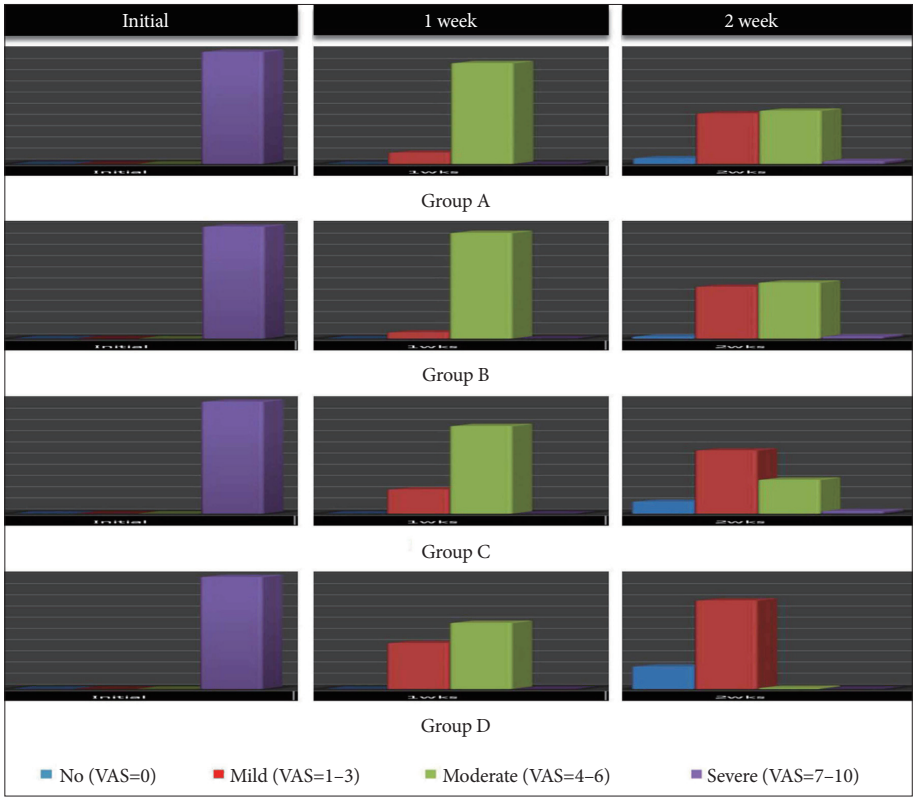

Fig. 4. Clinical assessment using the changes in visual analogue scale for each group. Taking the highest percentage of no and mild pain after treatment into consideration, the successful outcomes are seen in Group D.

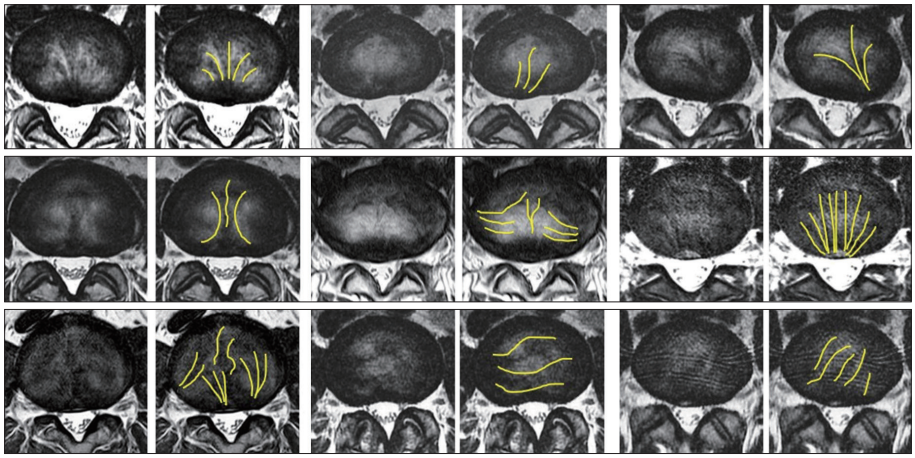

Fig. 5. Internal disc derangement pattern (left side : magnetic resonance imaging, right side : schematic diagram). These patterns of cracked nucleus pulposus may appear internal disc disruption, but some have intact annulus fibrosus. Including annular tear, all these patterns indicate the state of nucleus pulposus as derangement caused by increased intradiscal pressure. Internal disc derangement were observed in all groups.

nucleus pulposus was preserved to some degree. This finding was unlike anything seen in the case of an annular tear or internal disc disruption[4]. We considered that the naming of annular tear or internal disc disruption was focused on the state of annulus fibrosus. We named this state of the nucleus pulposus in patients with severe acute LBP as internal disc derangement (Fig. 5).

Acute loading stress, especially in lumbar flexion posture, could result in derangement of nucleus pulposus[1,2,11,21,35,39]. Inflammogenic nuclear substances cause epidural inflammation and dural irritation[38]. Therefore, the problem of anterior column could lead to a problem of middle column. Progression of nociceptive stimuli on the sinuvertebral nerve, dural irritation in the middle column and derangement of medial branch around the facet joint could result in referred pain it the same dermatome[29,30,36]. Furthermore, repeated flexion loading of the anterior column could lead to repeated stretch of the various viscoelastic tissues (ligaments, fascia, and facet capsule, etc.) of the posterior column[19,42]. Micro-damage of these tissues could affect posterior column to have ligament laxity around facet joints and derangement of the medial branches of the dorsal rami (Fig. 6)[20,40,41]. On the contrary, this state of ligament laxity around the facet joints could make the anterior column vulnerable to maintenance of intradiscal pressure[13]. RIT is needed for healing of damaged collagen fibers. We believe that the nucleus pulposus could be herniated or deteriorated through such a process, leading to degenerative changes such as internal disc disruption (Fig. 6)[37]. As a result, problem of 3-column within one segment could make a viscious cycle of segmental spine disease[12,14,20]. We refer to this segmental condition, mainly seen in

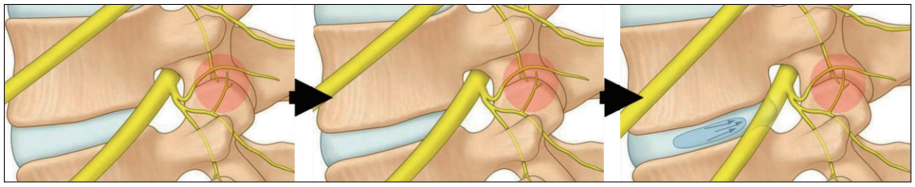

Fig. 6. Sequential diagrams representing the deep somatic derangement around a facet joint and medial branches of the dorsal rami after segmental subluxation. This change could make intervertebral disc vulnerable to be herniated.

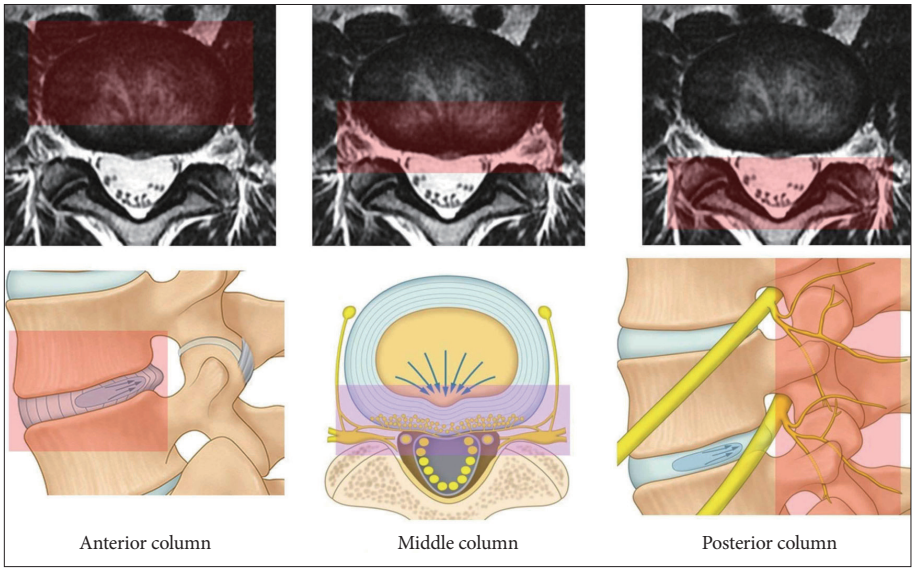

Fig. 7. The term "micro-subluxation" represents the status of 3-column distress. Anterior column has internal disc derangement and middle column has inflammatory reaction around nerves and dura. Finally posterior column has ligament laxity around facet joints and derangement of the medial branches of the dorsal rami.

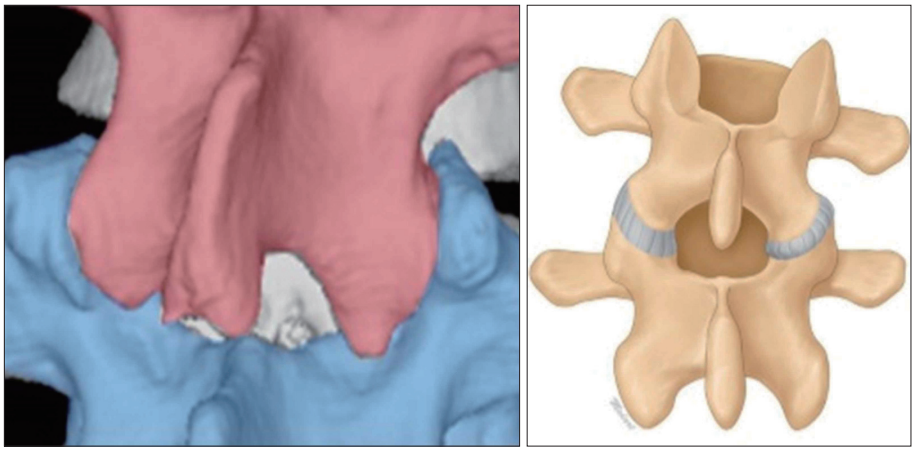

Fig. 8. The left figure shows micro-subluxation of facet joint in three dimensional computed tomography finding. The right figure is a schematic representation of micro-subluxation.

acute low back pain, as micro-subluxation (Fig. 7).

The concept of micro-subluxation is very similar to the chiropractic vertebral subluxation[18,22,23]. The World Health Organization (WHO) definition of the chiropractic vertebral subluxation is, "A lesion or dysfunction in a joint or motion segment in which alignment, movement integrity and/or physiological function are altered, although contact between joint surfaces remains intact. It is essentially a functional entity, which may influence biomechanical and neural integrity". This chiropractic subluxation at the spinal segment is different from anatomical subluxation seen on radiographs of patients with spondylolisthesis; therefore, it is functional subluxation. However, there is internal disc derangement and ligament laxity around facet joints between joint surfaces in our study. So we consider that micro-subluxation could be more suitable to represent segmental dysfunction than chiropractic vertebral subluxation (Fig. 8).

For treatment of the anterior column, we recommend postural reduction using a pillow under the lumbar curve for 30 min before sleep. Patient's symptom was the most improved in Group D statistically when compared with other groups. Maintenance of the lumbar lordotic curve decreases the flexion loading on the anterior column[3,5,11,34]. Moreover, postural reduction affects the posterior as well as the anterior columns. By doing so, the patients obtained safe reduction of micro-subluxation. Additionally, we have assumed that intradiscal pressure could decreases and the anterior column could have been restored. We have named this 3-column therapy as the segmental complex restoration (SCR) therapy.

There are several limitations in our study. We didn't evaluate the preexistence of the internal disc derangement before treat-

ment using MRI. So we are not sure that internal disc derangement is strictly the result from acute loading stress to intervertebral disc. And we didn't measure the intradiscal pressure. Additional experimental research should be needed to represent the decrease of intradiscal pressure after SCR therapy in practice. Finally, most patients had a short follow-up period because our study focused on a rapid pain management of severe acute LBP. Patients in all groups had rapid pain relief within 2 week.

CONCLUSION

We consider that the possible mechanism of severe acute low back pain after traumatic event originates from 3-column distress. Three-column distress within vertebral segment could result in a vicious cycle of spine disease such as discogenic pain, referred pain, and facet-joint origin pain. It is therefore better for the patient to undergo the SCR therapy with the segmental 3-column theory. Finally, the status of 3-column distress could appear as internal disc derangement on MRI.

REFERENCES

1. Adams MA, Dolan P : Could sudden increases in physical activity cause degeneration of intervertebral discs? **Lancet 350** : 734-735, 1997
2. Adams MA, McMillan DW, Green TP : Sustained loading generates stress concentration in lumbar intervertebral discs. **Spine 21** : 434-438, 1996
3. Alexander LA, Hancock E, Agouris I, Smith FW, MacSween A : The response of the nucleus pulposus of the lumbar intervertebral discs to functionally loaded positions. **Spine 32** : 1508-1512, 2007
4. Bartynski WS, Dejohn LM, Rothfus WE, Gerszten PC : 'Progressive-onset' versus injury-associated discogenic low back pain : features of disc internal derangement in patients studied with provocation lumbar discography. **Interv Neuroradiol 19** : 110-120, 2013
5. Beattie PF, Brooks WM, Rothstein JM, Sibbitt WL Jr, Robergs RA, MacLean T, et al. : Effect of lordosis on the position of the nucleus pulposus in supine subjects. A study using magnetic resonance imaging. **Spine 19** : 2096-2102, 1994
6. Crock HV : Internal disc disruption : A challenge to disc prolapse fifty years on. **Spine 11** : 650-653, 1986
7. Coppes MH, Marani E, Thomeer RTWM, Groen GJ : Innervation of "painful" lumbar discs. **Spine 22** : 2342-2350, 1997
8. da C Menezes Costa L, Maher CG, Hancock MJ, McAuley JH, Herbert RD, Costa LO : The prognosis of acute and persistent low-back pain : a meta-analysis. **CMAJ 184** : 613-624, 2012
9. Denis F : The three column spine and its significance in the classification of acute thoracolumbar spinal injuries. **Spine 8** : 817-831, 1983
10. Dishman R : Review of the literature supporting a scientific basis for the chiropractic subluxation complex. **J Manipulative Physiol Ther 8** : 163-174, 1985
11. Fennell AJ, Jones AP, Hukins DW : Migration of the nucleus pulposus within the intervertebral disc during flexion and extension of the spine. **Spine 21** : 2753-2757, 1996
12. Kong MH, Hymanson HJ, Song KY, Chin DK, Cho YE, Yoon do H, et al. : Kinetic magnetic resonance imaging analysis of abnormal segmental motion of the functional spine unit. **J Neurosurg Spine 10** : 357-365, 2009
13. Fujiwara A, Lim TH, An HS, Tanaka N, Jeon CH, Andersson GB, et al. : The effect of disc degeneration and facet joint osteoarthritis on the segmental flexibility of the lumbar spine. **Spine 25** : 3036-3044, 2000
14. Fujiwara A, Tamai K, An HS, Kurihashi T, Lim TH, Yoshida H, et al. : The relationship between disc degeneration, facet joint osteoarthritis, and stability of the degenerative lumbar spine. **J Spinal Disord 13** : 444-450, 2000
15. Hackett GS, Hemwall GA, Montgomery GA : **Ligament and Tendon Relaxation Treated by Prolotherapy**. G.A. Hackett Oak Park, IL : Hemwall, GA, 1991, pp94-100
16. Hildebrandt J : Relevance of nerve blocks in treating and diagnosing low back pain-is the quality decisive? **Schmerz 15** : 474-483, 2001
17. Jaumard NV, Welch WC, Winkelstein BA : Spinal facet joint biomechanics and mechanotransduction in normal, injury and degenerative conditions. **J Biomech Eng 133** : 071010(1-31), 2011
18. Kent C : Models of vertebral subluxation : A Review. **J Vert Sublux Res 1** : 1-6, 1996
19. King K, Davidson B, Zhou BH, Lu Y, Solomonow M : High magnitude cyclic load triggers inflammatory response in lumbar ligaments. **Clin Biomech (Bristol, Avon) 24** : 792-798, 2009
20. Kong MH, Morishita Y, He W, Miyazaki M, Zhang H, Wu G, et al. : Lumbar segmental mobility according to the grade of the disc, the facet joint, the muscle, and the ligament pathology by using kinetic magnetic resonance imaging. **Spine 34** : 2537-2544, 2009
21. Krag MH, Seroussi RE, Wilder DG, Pope MH : Internal displacement distribution from in-vitro loading of human thoracic and lumbar spinal motion segments. Experimental results and theoretical predictions. **Spine 12** : 1001-1007, 1987
22. Lantz CA : The vertebral subluxation complex part 1 : An introduction to the model and the kinesiological component. **J Chiropr Res 1** : 23-26, 1989
23. Lantz CA : The vertebral subluxation complex part 2 : The neuropathological and myopathological components. **J Chiropr Res 1** : 19-38, 1990
24. Linetsky F, Botwin K, Gorfine L, Jay GW, McComb B, Miguel R, et al. : Position paper of the florida academy of pain medicine on regenerative injection therapy : effectiveness and appropriate usage. **Pain Clin 4** : 38-45, 2002
25. Linetsky F, Manchikanti L : Regenerative injection therapy for axial pain. **Tech Reg Anesth Pain Manag 9** : 40-49, 2005
26. Linetsky F, Miguel R, Saberski L : Pain management with regenerative injection therapy (RIT), in Weiner RS (ed) : **Pain management : A practical guide for clinicians**. Washington DC : American Academy of Pain Management, 2002, pp381-401
27. Mehling WE, Gopisetty V, Bartmess E, Acree M, Pressman A, Goldberg H, et al. : The prognosis of acute low back pain in primary care in the United States : a 2-year prospective cohort study. **Spine 37** : 678-684, 2012
28. Miyakoshi N, Shimada Y, Kasukawa Y, Saito H, Kodama H, Itoi E : Total dorsal ramus block for the treatment of chronic low back pain : a preliminary study. **Joint Bone Spine 74** : 270-274, 2007
29. Mooney V, Robertson J : The facet syndrome. **Clin Orthop Relat Res 115** : 149-156, 1976
30. O'Neill CW, Kurgansky ME, Derby R, Ryan DP : Disc stimulation and patterns of referred pain. **Spine 27** : 2776-2781, 2002
31. Park WM, Kim K, Kim YH : Effects of degenerated intervertebral discs on intersegmental rotations, intradiscal pressures, and facet joint forces of the whole lumbar spine. **Comput Biol Med 43** : 1234-1240, 2013
32. Peng B, Hao J, Hou S, Wu W, Jiang D, Fu X, et al. : Possible pathogenesis of painful intervertebral disc degeneration. **Spine 31** : 560-566, 2006
33. Peng BG : Pathophysiology, diagnosis, and treatment of discogenic low back pain. **World J Orthop 4** : 42-52, 2013
34. Quinnell RC, Stockdale HR, Willis DS : Observations of pressures within normal discs in the lumbar spine. **Spine 8** : 166-169, 1983
35. Sato K, Kikuchi S, Yonezawa T : In vivo intradiscal pressure measurement in healthy individuals and in patients with ongoing back problems. **Spine 24** : 2468-2474, 1999
36. Schäfer A, Hall T, Briffa K : Classification of low back-related leg pain-a proposed patho-mechanism-based approach. **Man Ther 14** : 222-230, 2009
37. Schmidt H, Kettler A, Heuer F, Simon U, Claes L, Wilke HJ : Intradiscal pressure, shear strain, and fiber strain in the intervertebral disc under combined loading. **Spine 32** : 748-755, 2007

38. Sehgal N, Fortin JD : Internal disc disruption and low back pain. **Pain Physician 3** : 143-157, 2000
39. Seroussi RE, Krag MH, Muller DL, Pope MH : Internal deformations of intact and denucleated human lumbar discs subjected to compression, flexion, and extension loads. **J Orthop Res 7** : 122-131, 1989
40. Sihvonen T, Lindgren KA, Airaksinen O, Leino E, Partanen J, Hänninen O : Dorsal ramus irritation associated with recurrent low back pain and its relief with local anesthetic or training therapy. **J Spinal Disord 8** : 8-14, 1995
41. Sihvonen T : The segmental dorsal ramus neuropathy as a common cause of chronic and recurrent low back pain. **Electromyogr Clin Neurophysiol 32** : 507-510, 1992
42. Solomonow M : Neuromuscular manifestations of viscoelastic tissue degradation following high and low risk repetitive lumbar flexion. **J Electromyogr Kinesiol 22** : 155-175, 2012